



European Association of Urology



Reconstructive Urology

Failed Hypospadias Repair Presenting in Adults

Guido Barbagli^a, Michele De Angelis^b, Enzo Palminteri^a, Massimo Lazzeri^{c,*}

^a Center for Urethral and Genitalia Reconstructive Surgery, Arezzo, Italy

^b U.O. Urologia, Ospedale San Donato, Arezzo, Italy

^c Department of Urology, Santa Chiara-Firenze, Florence, Italy

Article info

Article history:

Accepted January 18, 2006

Published online ahead of
print on February 3, 2006

Keywords:

Hypospadias
Buccal mucosa
Urethroplasty
Graft
Flap

EU*ACME

www.eu-acme.org

Please visit

www.eu-acme.org to read
and answer the EU-ACME
questions on-line. The
EU-ACME credits will then
be attributed automatically.

Abstract

Objectives: To evaluate the results of one-stage and multistage urethroplasty in adults with complications following multiple failed hypospadias repairs.

Methods: Sixty adults underwent reconstructive surgery of the following complications after hypospadias repair: stricture (34), residual hypospadias (26), fistula (18), meatal stenosis (11), penile curvature (9), hair (4), diverticula (2), and stone (1). A total of 36% of the patients had one complication and 64% had two or more complications. Twenty-nine patients underwent one-stage repair with buccal or skin grafts or direct repair, and 31 underwent multistage repairs with buccal or skin grafts.

Results: Mean follow-up was 33.8 mo. Of the 60 cases, 45 (75%) had a final successful outcome and 15 (25%) failed. One-stage repair provided 24 (82.7%) successes and 5 (17.3%) failures. Multistage repair provided 21 (67.7%) successes and 10 (32.3%) failures. Buccal mucosa grafts provided 81% of success in one-stage procedures and 82.3% in multistage procedures. Penile skin grafts provided 80% of success in one-stage procedures and 50% in multistage procedures.

Conclusions: Adults with complications following childhood hypospadias repair are still a difficult population to treat with a high failure rate for reoperative surgery.

© 2006 Elsevier B.V. All rights reserved.

* Corresponding author. Department of Urology, Santa Chiara-Firenze, P.za Indipendenza, 11, 50129 Florence, Italy. Tel. +39 055 50381/+39 055 5038517; Fax: +39 055 480676.

E-mail address: lazzeri.m@tiscali.it (M. Lazzeri).

URL: www.santachiarafi.it

1. Introduction

Hypospadias is a congenital abnormality occurring in 1 of 300 live births and recent studies suggest an increase of the incidence with considerable

variation in different countries [1,2]. The current standard of care is to repair hypospadias with a one-stage procedure in the first year of life and on an outpatient basis [1,3]. Long-term reported success approaches 90% for all types of one-stage

hypospadias procedures, and with today's improved surgical techniques, complications of hypospadias surgery are seen less often [1,3,4]. Complications such as fistula, diverticulum, retrusive urethral meatus, residual chordee, and stricture require secondary surgery. Commonly, operative failures result from wound infection, urine extravasation, hematoma, ischemia, and necrosis of flap and graft or from errors in design, technique and postoperative care during primary repair [5,6]. Repeated attempts at surgical repair in these complicated cases are then less likely to succeed because the penis is densely scarred, immobile, hypovascular, or significantly shortened [6]. Hypospadias repair may fail also many years after a successful functional and aesthetic result of the primary repair. Pediatric urologists recently emphasized that these patients should be reassessed at puberty and again at mid-teens when the genital maturation is nearly complete because the neourethra may fail to grow adequately and, therefore at a certain point, become narrow. We need to maintain active follow-up on these patients until they have reached full sexual maturity and activity [3,7,8].

We report the results of our surgical experience on 60 adults with complications after multiple failed hypospadias repairs, comparing the results of numerous and different surgical techniques used in repairing these urethral and penile defects. Moreover, we discuss the etiology of these complications, emphasizing the role that the lack of spongiosum tissue could play in this difficult population of patients.

2. Patients and methods

We retrospectively reviewed the clinical history and charts of 60 patients evaluated and treated in our centers, from 1995 through 2004, for complications after failed hypospadias repair. The age of patients ranged between 19 and 37 yr (mean, 32.2 yr). All patients had undergone a variety of primary hypospadias corrections in the past, ranging from one to more than eight procedures. The average number of previous operations was 1.9. Some patients, who had undergone more than two or three operations several years before we saw them, often lost count of the exact number of surgeries and were not able to indicate the exact location of the primary original meatus or whether the surgical technique used for repair was a one-stage or multistage procedure. A review of these cases reveals no common factors in the failures. Several techniques were used by different surgeons to correct various kinds of primary hypospadias and complications resulting from this primary repair. Preoperatively, all patients underwent urine culture, retrograde and voiding cystourethrography, and urethroscopy using a pediatric instrument. Patients

Table 1 – Complications after failed hypospadias repair

Complication	No. of patients	%
Urethral stricture	34	56.6
Residual hypospadias	26	43.3
Fistula	18	30
Meatal stenosis	11	18.3
Penile curvature	9	15
Hair	4	6.6
Diverticula	2	3.3
Stone	1	1.6

with residual penile or glans curvature were asked to supply photos of the penis in full erection.

The complications in these 60 patients are shown in Table 1. Twenty-two patients (36.6%) had one complication, 26 patients (43.4%) had two complications, 8 patients (13.4%) had three complications, and 4 patients (6.6%) had four complications. A total of 105 complications was reported in our 60 patients.

We divided these 60 complicated hypospadias cases into five groups based on the surgical techniques used for correction. Group 1 included 8 patients who had a one-stage direct repair without grafting the urethra: one meatoplasty, one anastomotic repair, and six fistula closures. Group 2 included 10 patients who had a one-stage repair with skin: seven dorsal inlay grafts and three penile flaps. Group 3 included 11 patients who had a one-stage repair with buccal mucosa (BM): six dorsal inlay grafts, and five ventral onlay grafts. Group 4 included 14 patients who underwent a multistage repair with skin. Group 5 included 17 patients who underwent a multistage repair with BM (Table 2). The skin was used at the beginning of our experience.

Follow-up ranged from 12 to 138 mo (mean, 33.8 mo). Uroflowmetry was used in all patients to assess the voiding phase of micturition reflex. Patients with subjective symptoms of decreased urinary stream and a maximum flow rate of <12 ml/s underwent a meatal calibration or retrograde urethrography and urethroscopy. Patients presenting with residual chordee were asked to supply again photos of the penis in full erection. We decided to avoid the indiscriminate use of invasive diagnostic tools in the follow-up because all these patients were used to undergoing repeated urethral manipulations or invasive radiologic tests before surgery.

Success was defined by having a functional urethra without fistula, stricture, or residual chordee and having a

Table 2 – Surgical techniques

8 one-stage direct repairs	meatoplasty 1 fistula closure 6 anastomotic repair 1
10 one-stage repairs with skin	dorsal inlay grafts 7 penile flaps 3
11 one-stage repairs with buccal mucosa	dorsal inlay grafts 6 ventral onlay grafts 5
14 multistage repair with skin	
17 multistage repair with buccal mucosa	

cosmetically acceptable glandular meatus after completion of all secondary procedures. The necessity of meatal or urethral dilation and the presence of complications or a poor aesthetic result requiring revision were considered failures. All patients were evaluated at the end point of the surgical itinerary.

No formal statistical analysis was performed because of the small sample size, which was observed over a long period, from 1995 to 2004.

3. Results

Of 60 cases, 45 (75%) were classified successes and 15 (25%) as failures (Table 3). One-stage repair provided 87% success in eight direct repairs without grafts, 80% success in one-stage techniques using penile skin, and 82% success in one-stage techniques using BM (Table 3). Multistage repairs provided 50% success with penile skin and 82% success with BM (Table 3). Fistula (1 case) was the cause of failure in a one-stage direct repair. Meatal stenosis (2 cases) and fistula (2 cases) were the causes of failure in one-stage repair with skin or BM. Glans dehiscence (3 cases), meatal stenosis (2 cases), fistula (2 cases), poor aesthetic result (2 cases), and residual chordee (1 case) were the causes of failures in multistage repairs with skin or BM.

The BM grafts provided 82% success in one-stage procedures and 82% in multistage procedures (Table 3). Penile skin grafts provided 80% success in one-stage procedures and 50% in multistage procedures (Table 3). The one-stage direct repair without graft provided a higher success rate (87%) when compared to one-stage repair with skin grafts (80%) or BM (82%; Table 3), but these procedures were selected for simple cases, not requiring the use of substitution material for the urethral reconstruction. The one-stage techniques provided higher success rates when compared to multistage techniques: 80% versus 67%. In one-stage procedures the use of BM or penile skin grafts showed the same success rate: 82% versus 80%. On the other hand, in multistage procedures the BM was superior to the

penile skin, showing a higher success rate: 82% versus 50%. Only 61% of the patients who underwent multistage techniques required two surgical steps before the final urethral reconstruction and 39% of the cases required more than two surgical steps before the final urethral reconstruction.

4. Discussion

The management of complications in adults, in whom multiple attempts of hypospadias repair had failed, is a surgical challenge and still represents a complex problem for reconstructive urologists. Often this difficult population of patients has been left with deformities significantly worse than the primary congenital anomaly [4,6]. Moreover, the results of hypospadias repair in adulthood are worse than those of similar procedures in childhood and represent clearly a difference in terms of wound healing, infection, complications rates, and overall success [9,10]. Penile urethroplasty, whether a one-stage or a multistage repair, is intrinsically prone to complications such as hematoma or infection, which in turn can lead to secondary complications such as fistula, which do not occur in the bulbar or posterior urethra; it is the one most likely to produce alterations in sexual function [11]. Therefore, penile urethral stricture always represents a more difficult challenge in patients with failed hypospadias repair. It is the consequence of paucity of local skin and lack of corpus spongiosum that represents the basic tissue, which warrants adequate vascular and mechanical support to transplanted substitute material used for urethroplasty.

In 1941, Humby, pioneer of one-stage hypospadias repair using free grafts, described the use of buccal graft harvested with “some misgivings” from lower lip, in an 8-yr-old boy who had had many operations for hypospadias that resulted in a penoscrotal fistula [12,13].

In 1973, Devine and Horton were the first to clarify the embryologic, anatomic, clinical, and surgical relationships between hypospadias and chordee [14,15], and the first to create the term “hypospadias cripple” to emphasize the complexity of these deformities [6]. Devine et al., reviewing data on 70 adults with failed hypospadias repair, identified a list of errors in hypospadias surgery (errors in evaluation, designs, technique, and postoperative care) and suggested a list of numerous surgical techniques for repair of these defects with the use of local flaps for one-stage urethral reconstruction [4,5]. Later, the use of pedicled flap urethroplasties (Mathieu-flip-flap technique) was considered a

Table 3 – Results of the surgical repair

Surgical techniques	No. of patients	Success	Failure
One-stage direct repair	8	7 (87%)	1 (13%)
One-stage repair with skin	10	8 (80%)	2 (20%)
One-stage repair with buccal mucosa	11	9 (82%)	2 (18%)
Multistage repair with skin	14	7 (50%)	7 (50%)
Multistage repair with buccal mucosa	17	14 (82%)	3 (18%)
Total	60	45 (75%)	15 (25%)

salvage procedure by the use of penile skin that has been relocated during prior hypospadias repair. It was reported by other authors to have a high success rate [16,17].

In 1992, Burger et al. reported the use of BM for repair of complications following childhood hypospadias surgery [18]. The buccal grafts were used either as a tube or patch in a one-stage operation with three postoperative fistulas requiring a new surgical approach and one meatal stenosis managed by simple dilation with satisfactory final outcome in all patients [18]. After the Burger article, numerous reports appeared on the use of the BM grafts in repair of complications after failed hypospadias surgery. Unfortunately, the majority of these studies mixed both children and adults or patients with epispadias or urethral stricture without hypospadias; therefore, it is not possible to extrapolate from the overall complication rates the results that the authors obtained, particularly in adults with failed hypospadias repair [19–23].

In 1995, Bracka presented a two-stage penile skin graft technique for repairing complications after failed hypospadias in 121 adults [24,25]. This method did not claim substantial originality but, rather, represented a further refinement and evolution of existing surgical techniques suggested for hypospadias surgery. The author concluded that a two-stage repair by splitting the glans and lining it with penile skin or BM grafts (to allow a subsequent terminalization of the meatus), was extremely adaptable and produced sophisticated results in any degree of deformity with skin-deficient “hypospadias cripple” [24,25]. Nevertheless, about 10% of the patients required revision of the first stage of their repair or underwent further cosmetic adjustment after completion of their repairs [24,25]. In 2004, Snodgrass and Elmore, pioneers of one-stage hypospadias surgery, reported the initial experience with 25 staged buccal graft (Bracka) urethroplasties after failed hypospadias surgery [26]. Of the 25 cases, 12% required a second grafting procedure before tubularization and four partial glans dehiscences occurred after tubularization, requiring reoperative glansplasty [26]. In this initial experience, seven patients (35%) showed complications, including fistulas after second-stage closure, which led to another surgical procedure [26].

Numerous surgical techniques have been suggested to repair the complications after failed hypospadias repair in adults including one-stage procedures (flaps-flaps, onlay flaps, tubularized preputial flaps or tubularized incised plate urethroplasties, bladder mucosa graft) or multistage procedures with penile skin or BM and renewed

controversy exists over the best means of reconstructing the penile urethra in this difficult population of patients [27–29]. The current literature does not clearly support us in the choice of either the use of penile graft or flap urethroplasty. Comparison of flaps versus grafts has been carried out only in children with proximal hypospadias [30], making it difficult to declare a clear winner. Complication rates ranging from 14% to 56% have been reported following reoperative flap urethroplasties [4,16,17], which have raised doubts that these tissues, with their inherent blood supply, are superior to grafts, which must re-establish vascularity from a scarred recipient bed [26]. Moreover, tubularized incised plate reoperations have complication rates of 15–24% [26,31]. The use of BM as substitute material in one-stage procedures showed complications requiring further surgery in 24–57% of the patients [20–23,26]. Instead, multistage procedures using BM grafts showed complication rates of 10–35% [25,26].

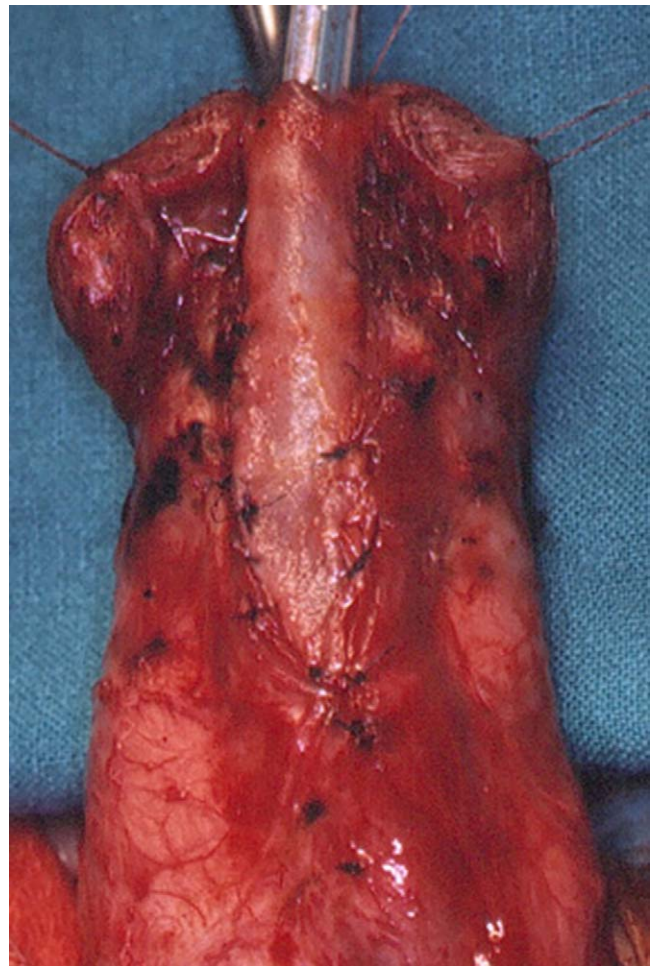


Fig. 1 – One-stage ventral onlay buccal mucosa technique. The graft is applied on ventral urethral surface onto the original urethral plate. The spongiosum tissue of glans is used to cover the graft.

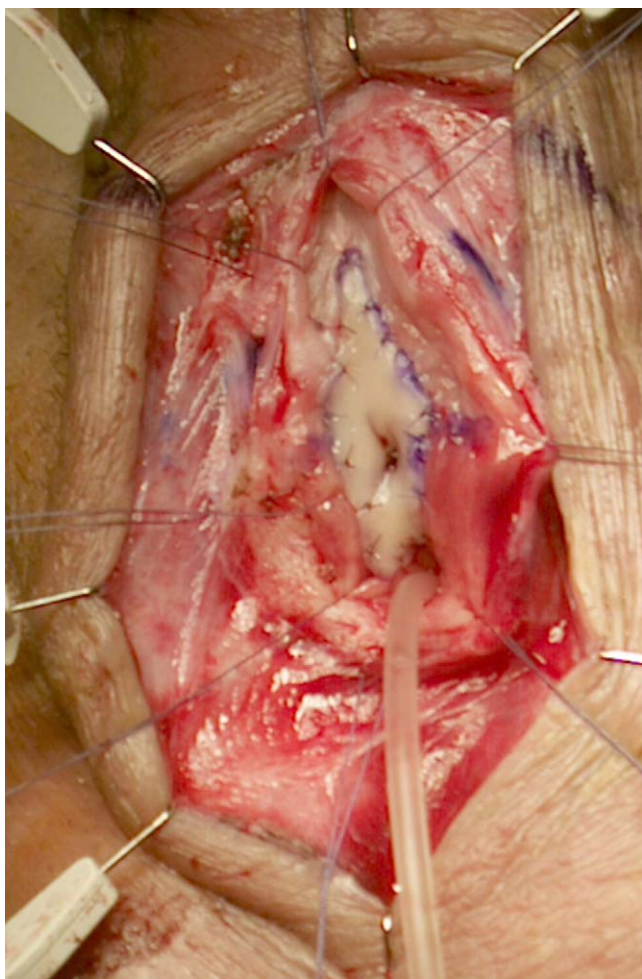


Fig. 2 – One-stage dorsal inlay buccal mucosa technique. The original urethral plate is incised on the mid-line (Snodgrass) and the buccal graft is sutured on dorsal urethral plate surface. The urethra is closed over a 12 Fr Foley catheter.

In our experience, 39% of the patients required more than two planned surgeries. It was due to the complications after the first stage, such as contracture of the initial graft, which required a new grafting procedure (Fig. 5). Moreover, the second stage showed fistula, glans dehiscence, and meatal stenosis as common complications as reported by others [26]. In 1941, Humby suggested that in hypospadias repair, the customary three-stage operations frequently had to be extended to many more before the final result could be considered adequate [16]. In 2004, Shukla et al. suggested that the two-stage hypospadias repair is a misnomer because this technique rarely required only two stages and 70% of cases required at least one additional procedure (mean, 1.6 procedures) to obtain satisfactory results [32]. Moreover, these repeated surgical revisions might have a tremendous psychological impact on the patient [33–35].

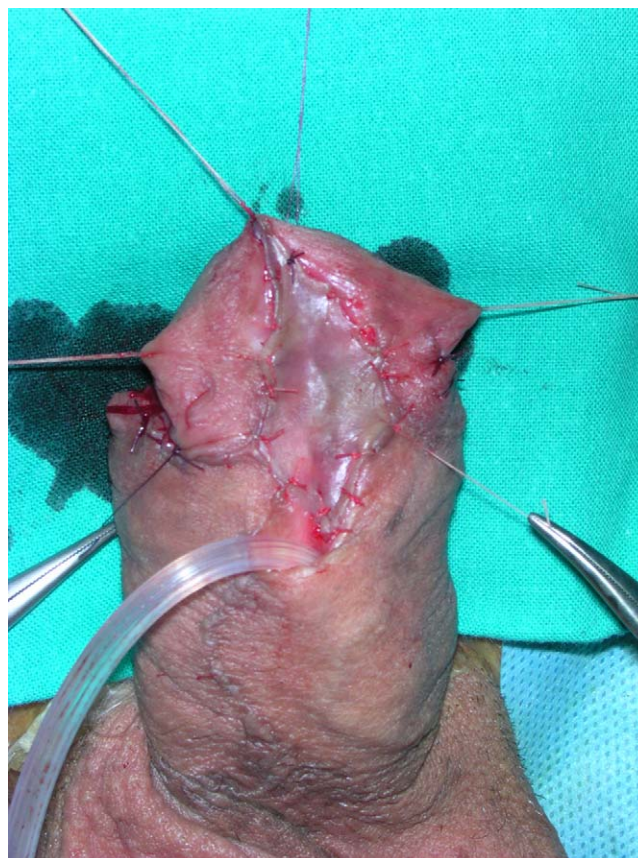
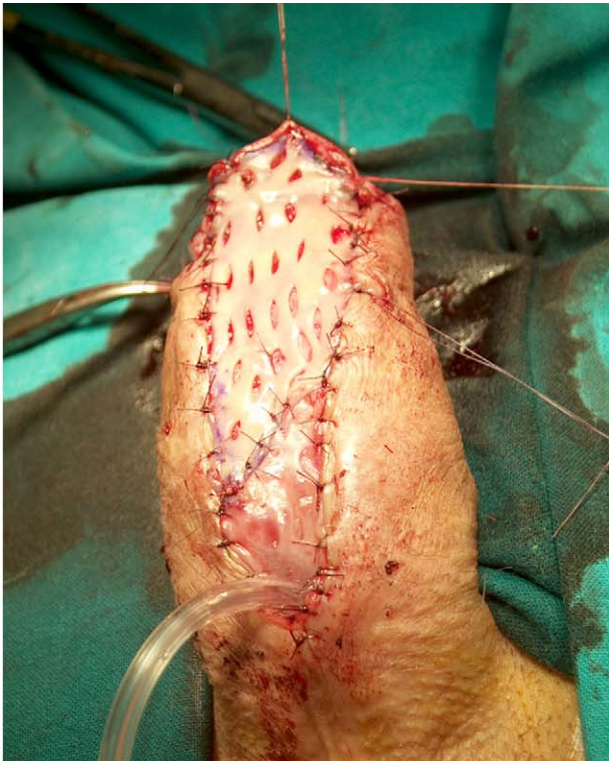
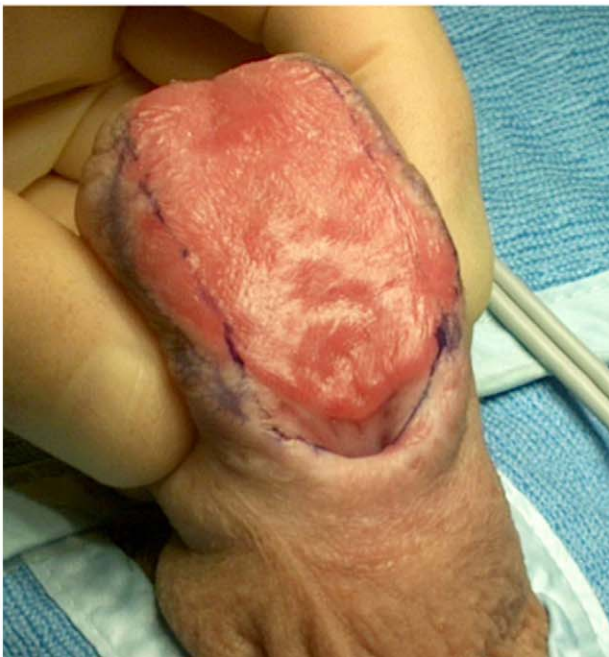
Fig. 3 – Multistage procedure using penile skin. The original urethral plate is removed and the skin graft is applied on the fully opened glans.

We have treated 105 complications in 60 patients using seven different one-stage procedures (Figs. 1 and 2) and two different multistage procedures with penile skin or BM as substitute material (Figs. 3–5). All the surgeries were performed by the same urologist (G.B.). The failure/complication rate was uniformly distributed in all kinds of repairs: 13% in one-stage direct repair (1 meatoplasty, 1 end-to-end, 6 fistula closure), 20% in one-stage repair with penile skin (3 flaps, 7 grafts), 18% in one-stage repair with BM (6 dorsal inlays, 5 ventral onlays), 50% in multistage repair with penile skin, 18% in multistage repair using BM. Consequently, at our centers all patients, who are selected for a one-stage procedure, are fully informed that any surgical technique may be complicated, both at early and later stages, including complications such as hematoma, infection, meatal stenosis, or fistula. All patients requiring multistage urethroplasty are fully informed that more than two surgical steps could be necessary to restore both urethral patency and acceptable aesthetic appearance of genitalia. Urethral structures were the most frequent complication (56.6%), and



(a)



(b)

Fig. 4 - Multistage procedure using buccal mucosa. (A) The original urethral plate is fully removed, the glans is opened, and the graft is sutured and quilted on the corpora cavernosa. (B) Excellent appearance of the buccal mucosa graft 6 mo after the transplant.

the management of these strictures was made using a one-stage technique in uncomplicated cases and multistage repair when the strictures were associated with local adverse conditions, such as fistula,

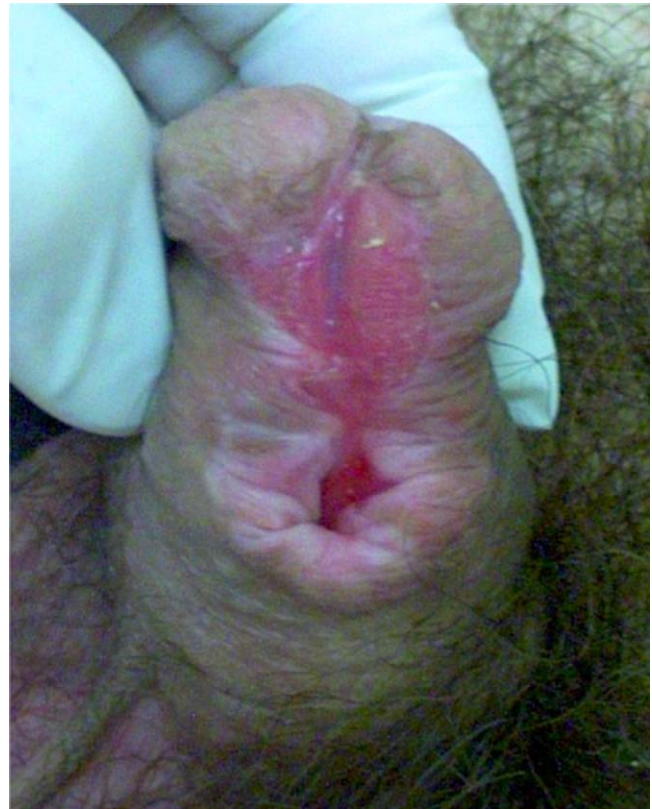

Fig. 5 - Multistage procedure using buccal mucosa. Unsatisfactory appearance of the buccal mucosa graft 6 mo after the transplant, requiring surgical revision before the final urethral closure.

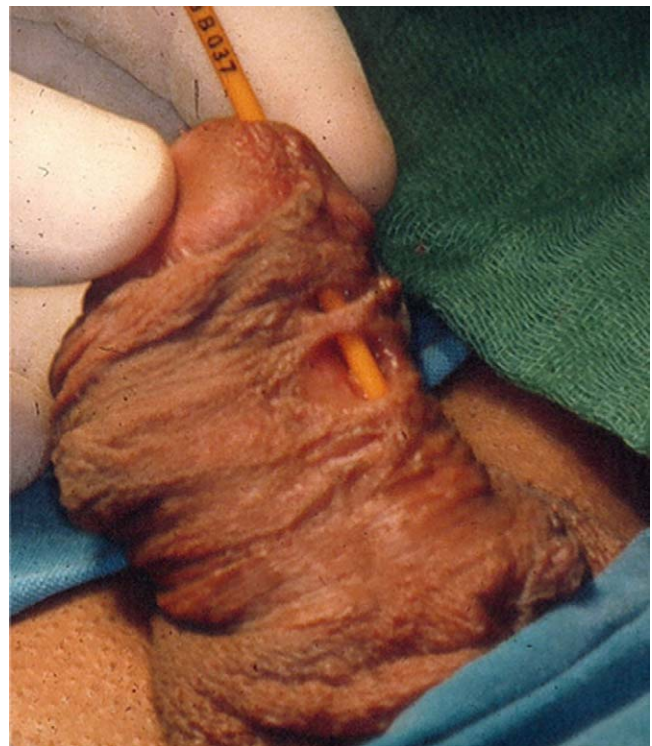


Fig. 6 - Multiple urethral and penile deformities in patients with failed hypospadias repair.

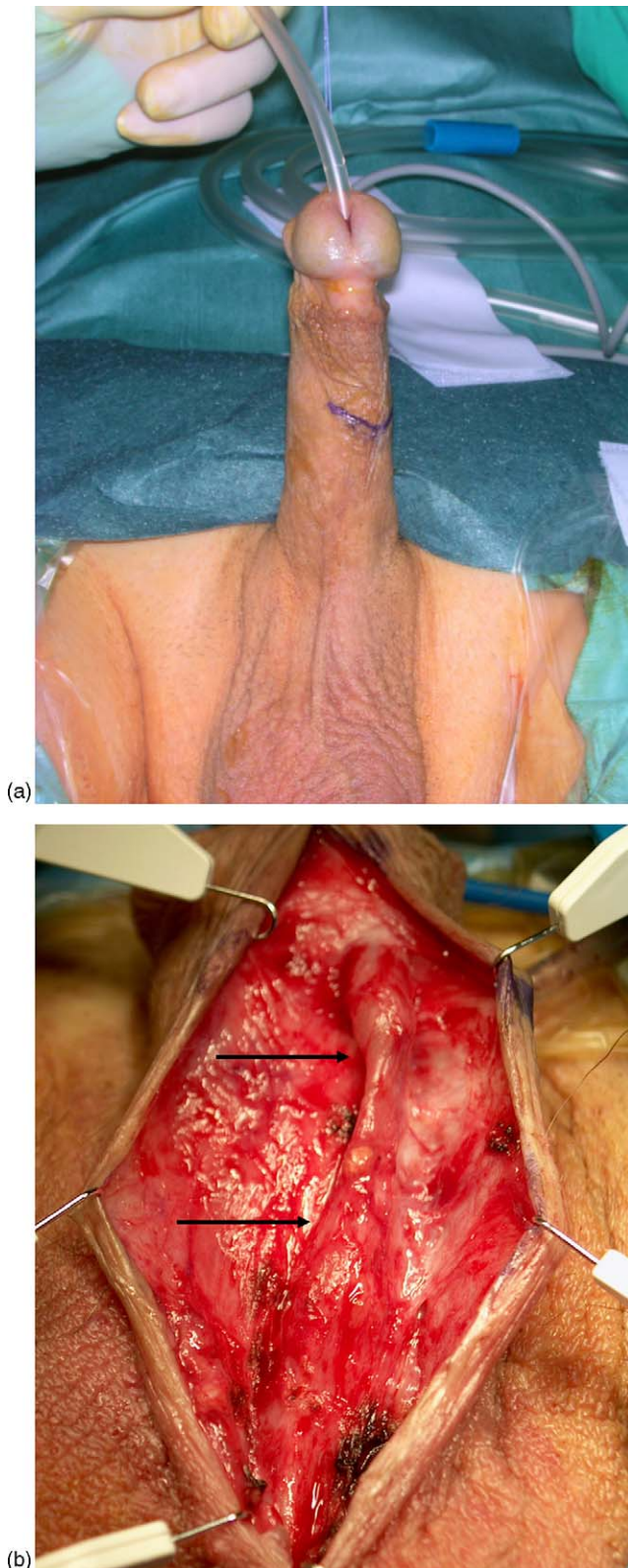


Fig. 7 – Urethral stricture in adult patient following failed hypospadias with satisfactory aesthetic outcome. (A) The Nelaton 16 Fr catheter inserted through the external urinary meatus stop after 3 cm (broken line outlined on penile skin). (B) The urethral narrowing and the lack of spongiosum tissue are evident in this skin-made urethra (2 arrows).

paucity of penile skin, residua curvature, poor aesthetic appearance, and others.

Our experience with 60 adults showed two different populations in whom attempts at surgical correction of hypospadias have failed. Some patients showed multiple penile deformities significantly worse than the primary congenital anomaly, such as fistula, residual hypospadias, penile curvature, and cosmetically unacceptable glans appearance (Fig. 6). These were caused by evident errors in evaluation, design, techniques, or post-operative care during the primary repair of hypospadias, as suggested by Devine et al. [5]. These patients have undergone numerous surgeries to repair penile defects without a satisfactory outcome and preferred to wait for many years before further surgical attempts. Now they ask again for correction of these deformities. On the other hand, some patients showed a satisfactory outcome of primary hypospadias repair, having a cosmetically acceptable glandular meatus and penis with no evident deformities as fistula or retrusive meatus or chordee and the prevalent complication was a urethral stricture (Fig. 7). These patients have completed the repair of hypospadias during infancy and the reconstructed urethra provided normal urinary stream for many years. Usually, these patients showed increasing urinary problems and difficulties 10, 12, or 15 yr after the surgery, when the pediatric follow-up was stopped and patients were fully involved in sexual activity. We suppose that, in these patients, it is the congenital lack of spongiosum tissue that promotes the urethral deterioration over time. Probably, the skin-made urethra (Fig. 7B) does not tolerate the repeated stretch and trauma during erection and sexual activity as spongiosum-made urethra is used to tolerate. As an analogy, during sexual activity, the corpus spongiosum is to the urethra what the airbag is for the body during a car accident.

5. Conclusions

In adults with complications after failed hypospadias repair, all urethroplasty procedures, despite meticulous technique, have the potential to fail and any substitute material can deteriorate over time. Consequently, it is mandatory to extend the follow-up beyond puberty or to such time that genital maturation is completed.

The best technique is probably the one with which the surgeon is most comfortable and it could be appropriately tailored on the single patient, based on the proper anatomic characteristics that the

urethral plate, penile skin, glans shape, and dartos fascia provide to ensure flap or graft taking and survival. No single technique is appropriate for all situations and the successful surgeon will have a repertoire of methods from which to choose and the use of flaps or grafts should not compromise penile length, should not cause penile chordee, and certainly should not untowardly affect penile appearance. It is a useful reminder to readers that this is a challenging surgery and should not therefore be undertaken by surgeons who only dabble in this field.

In the near future, tissue engineering technology could provide a new urethra with normal spongiosum tissue around the mucosal-urothelium strip, offering urologists a higher quality substitute material with which to work.

References

- [1] Baskin LS. Hypospadias and urethral development. *J Urol* 2000;163:951–6.
- [2] Thomas DFM. Hypospadiology: science and surgery. *BJU Int* 2004;93:470–3.
- [3] Manzoni G, Bracka A, Palminteri E, Marrocco G. Hypospadias surgery: when, what and by whom? *BJU Int* 2004;94:1188–95.
- [4] Secrest CL, Jordan GH, Winslow BH, et al. Repair of the complications of hypospadias surgery. *J Urol* 1993;150:1415–8.
- [5] Devine CJ, Franz JP, Horton CE. Evaluation and treatment of patients with failed hypospadias repair. *J Urol* 1978;119:223–6.
- [6] Stecker JF, Horton CE, Devine CJ, McCraw JB. Hypospadias cripples. *Urol Clin North Am* 1981;8:539–44.
- [7] Snodgrass WT. Assessing outcomes of hypospadias surgery. *J Urol* 2005;174:816–7.
- [8] Bracka A. Sexuality after hypospadias repair. *BJU Int* 1999;83:29–33.
- [9] Hensle TW, Tennenbaum SY, Reiley EA, Pollard J. Hypospadias repair in adults: adventures and misadventures. *J Urol* 2001;165:77–9.
- [10] Senkul T, Karademir K, Iseri C, Erden D, Baykal K, Adayener C. Hypospadias in adults. *Urology* 2002;60:1059–62.
- [11] Andrich DE, Leach CJ, Dunglison N, Mundy AR. The problems of penile urethroplasty. *J Urol* 2002;167:84 (abstract no. 334).
- [12] Humby G. A one-stage operation for hypospadias. *Br J Surg* 1941;29:84–92.
- [13] Etker S. RE: Buccal mucosal urethral replacement [letter]. *J Urol* 1996;155:1395.
- [14] Devine CJ, Horton CE. Chordee without hypospadias. *J Urol* 1973;110:264–71.
- [15] Devine CJ, Horton CE. Use of dermal graft to correct chordee. *J Urol* 1975;113:56–8.
- [16] Jayanthi VR, McLorie GA, Khoury AE, Churchill BM. Can previously relocated penile skin be successfully used for salvage hypospadias repair? *J Urol* 1994;152:740–3.
- [17] Simmons GR, Cain MP, Casale AJ, Keating MA, Adams MC, Rink RC. Repair of hypospadias complications using the previously utilized urethral plate. *Urology* 1999;54:724–6.
- [18] Bürger RA, Müller SC, El-Damanhoury H, Tschakaloff A, Riedmiller H, Hohenfellner R. The buccal mucosal graft for urethral reconstruction: a preliminary report. *J Urol* 1992;147:662–4.
- [19] Duckett JW, Coplen D, Ewalt D, Baskin LS. Buccal mucosal urethral replacement. *J Urol* 1995;153:1660–3.
- [20] Yerkes EB, Adams MC, Miller DA, Brock JW. Coronal cuff: a problem site for buccal mucosal grafts. *J Urol* 1999;162:1442–4.
- [21] Metro MJ, Wu H, Snyder HM, Zderic SA, Canning DA. Buccal mucosal grafts: lessons learned from an 8-year experience. *J Urol* 2001;166:1459–61.
- [22] Hensle TW, Kearney MC, Bingham JB. Buccal mucosa grafts for hypospadias surgery: long-term results. *J Urol* 2002;168:1734–7.
- [23] Fichtner J, Filipas D, Fisch M, Hohenfellner R, Thüroff JW. Log-term followup of buccal mucosa onlay graft for hypospadias repair: analysis of complications. *J Urol* 2004;172:1970–2.
- [24] Bracka A. A versatile two-stage hypospadias repair. *Br J Plast Surg* 1995;48:345–52.
- [25] Bracka A. Hypospadias repair: the two-stage alternative. *Br J Urol* 1995;76:31–41.
- [26] Snodgrass W, Elmore J. Initial experience with staged buccal graft (Bracka) hypospadias reoperations. *J Urol* 2004;172:1720–4.
- [27] Li L, Zhang X, Zhou S, Zhou X, Yang W, Zhang Y. Experience with repair of hypospadias using bladder mucosa in adolescents and adults. *J Urol* 1995;153:1117–9.
- [28] Minor TX, Alsikafi NF, McAninch JW. Adult urethral reconstruction of complications following childhood hypospadias repair. *J Urol* 2004;171:17 (abstract no. 63).
- [29] Barbagli G, Palminteri E, Guazzoni G, Turini D, Lazzeri M. One-stage and multi-stage penile urethroplasty in 60 adult patients after failed hypospadias repair: comparison between penile skin and buccal mucosa grafts. *J Urol* 2005;173:89 (abstract no. 322).
- [30] Powell CR, Mcaleer I, Alagiri M, Kaplan GW. Comparison of flaps versus grafts in proximal hypospadias surgery. *J Urol* 2000;163:1286–9.
- [31] Borer JG, Bauer SB, Peters CA, et al. Tubularized incised plate urethroplasty: expanded use in primary and repeat surgery for hypospadias. *J Urol* 2001;165:581–5.
- [32] Shukla AR, Patel RP, Canning DA. The 2-stage hypospadias repair. Is it a misnomer? *J Urol* 2004;172:1714–6.
- [33] Aho MO, Tammela OKT, Tammela TLJ. Aspects of adult satisfaction with the result of surgery for hypospadias performed in childhood. *Eur Urol* 1997;32:218–22.
- [34] Woodhouse CRJ, Christie D. Nonsurgical factors in the success of hypospadias repair. *BJU Int* 2005;96:22–7.
- [35] Nelson CP, Bloom DA, Kinast R, Wei JT, Park JM. Long-term patient reported outcome and satisfaction after oral mucosa graft urethroplasty for hypospadias. *J Urol* 2005;174:1075–8.

Editorial Comment

Aivar Bracka, Consultant Genito-Urethral Plastic Surgeon, Plastic Surgery Unit

Liz.Warby@dgoh.nhs.uk

This paper is a welcome addition to the relatively sparse literature on the subject of adult hypospadias revision. Unfortunately, despite a cohort of 60 patients, the papers shares some limitations with other similar publications, in that it deals with a heterogeneous assortment of problems and solutions, with insufficient numbers in individual categories to allow or statistically meaningful assessment. Nevertheless, the authors have made some interesting observations and drawn controversial conclusions which merit further consideration.

Strictureing of the neo-urethra or meatus was by far the commonest presenting problem. It is therefore disappointing, and I think a serious omission, that the aetiology and management of hypospadias strictures was not adequately discussed.

There are essentially 2 types of hypospadias stricture. The 1st type arises from mechanical problems with the design, execution or aftercare of the surgery and is straightforward to manage. If very minor, then a simple dilation may suffice, otherwise if more severe or recurring, then a dorsal inlay patch graft will solve the problem.

These solutions do not apply to the 2nd type of stricture, which assumes particular relevance in these adult salvage cases. The authors rightly observe that strictures sometimes develop insidiously long after an apparently successful hypospadias repair.

They speculate that late structuring develops because the new urethra is devoid of supporting corpus spongiosum. Given that spongioplasty is only a very recent trend in primary hypospadias repair, it is likely that most of the adults in their study group share this particular anatomical deficit. One might therefore expect stricture formation to be a fairly universal problem among adults with repaired hypospadias, yet this is not the case. Indeed, one might expect attach of mechanical support to cause dilation rather than structuring, a feature that is common after tubed preputial repairs.

Another reviewer suggested that adult strictures might develop because a scarred or poorly vascularised urethra fails to grow adequately during adolescence. Whilst a plausible explanation in some cases, it still overlooks the most important cause of the recalcitrant adult stricture or “hypospadias cripple.”

From a personal experience of now over 500 adult hypospadias re-operative cases, around 160 have clinical and histological evidence of lichen

sclerosus (LS), otherwise known as balanitis xerotica obliterans (BXO), and there are further cases where this diagnosis is likely but not proved.

The authors have actually illustrated at least one florid case Fig. 5 shows clear evidence of LS in the skin around the meatus. I suspect that LS is also present in 4b (4a is a different patient as evident for the position of the genital raphe).

It is perhaps fortuitous that the authors chose the correct treatment in both these patients, i.e. 2 stage buccal mucosal substitution of the diseased segment of urethra. Any other treatment would have eventually led to stricture recurrence. This is however a method that they only introduced later in their study period and whilst now buccal muscosa may have largely superseded skin reconstructions. Notwithstanding improvements as they progressed along their leaning curve with the use of free grafts, LS may contribute to the authors’ relatively poor results with staged skin urethroplasty. Any form of skin urethroplasty is contra-indicated in presence of LS [1].

The high incidence of graft complications in their staged repairs is disconcerting and certainly somewhat greater than has been my own experience. However, this may be largely due to technical errors associated with their early free graft learning curve, and I feel that a further audit of their next 60 patients would produce a different outcome. I note from several of the pictures that there is a paucity of quilting sutures to fix the graft onto the wound bed. Secure fixations of the graft to the wound bed is important for reliable “take.” Furthermore there may have been a tendency to make the grafts a little narrower than ideal as in Fig. 4a, leading subsequently to a tight urethral closure. A wider graft as in Fig. 4b (a buccal graft from later in their series) if preferable, as this allows for some degree of contraction that may or may not take place during the healing phase. Lateral surplus can always be discarded at the 2nd stage.

Despite these few criticisms and comments, I nevertheless congratulate the authors in presenting an informative and very candid account of their experience with adult hypospadias. I would fully concur with their principal take home message, that hypospadias complications presenting in adults can be challenging and difficult to correct, even in the hands of experienced urethral surgeons.

Reference

- [1] Depasquale I, Park AJ, Bracka A. The treatment of balanitis xerotica obliterans. *BJU International* 2000;86:459–65.